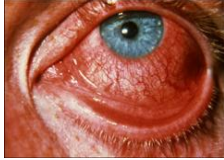

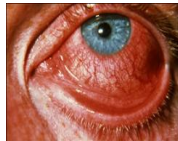The Red Eye



Stuart Fourman, M.D.
Department of Ophthalmology
SUNY Stony Brook

The Red Eye

- History
 - One, both eyes
 - Recent URI, exposure
 - Eyes crusted shut
- Exam
 - Vision
 - Pupils
 - Look at eye



The Red Eye

- Differentiate benign from visually threatening causes
- Benign: normal vision, normal pupils
- Visually threatening: decreased vision, abnormal pupils

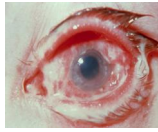The Red Eye

- Acute Conjunctivitis
 - viral, bacterial, allergic, neonatal
- Blepharitis
- Foreign Body
- Subconjunctival Hemorrhage
- Corneal Ulcer
- Acute Iritis
- Scleritis
- Acute Glaucoma

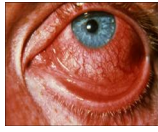The Red Eye

- Acute Conjunctivitis
- lids crusted shut
 - viral, bacterial, allergic
 - bacterial--purulent
 - allergic---itching
 - viral---URI, PAN
 - Rx-decongestant,
weak antibiotic
 - possible contagion

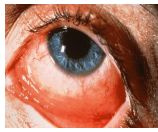
bacterial



viral

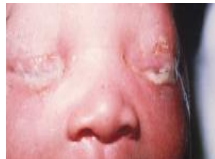

allergic



The Red Eye

- Neonatal Conjunctivitis
 - Special entity
 - Timing after birth
 - Less than 24 hrs, chemical
 - 24-48 hrs-GC
 - After 48 hrs-other bacteria
 - 1-5 days-HSV
 - 5-10 days-chlamydia
 - Swollen eyelids, chemosis, pus
 - May need scrapings, cultures
 - Complicated by ulcers
 - Topical Erythromycin prophylaxis
 - May need systemic therapy

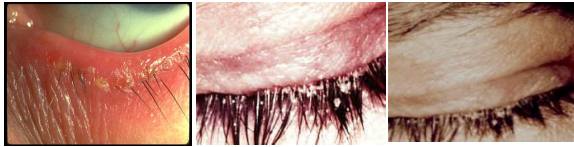
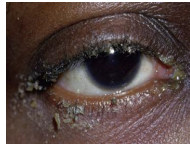


The Red Eye

- Acute Conjunctivitis
viral, bacterial, allergic, neonatal
- **Blepharitis**
- Foreign Body
- Subconjunctival Hemorrhage
- Corneal Ulcer
- Acute Iritis
- Scleritis
- Acute Glaucoma

The Red Eye

- Blepharitis
 - Very common
 - Long duration-weeks, months
 - Crusting over lids, dandruff
 - Use of eyelid makeup
 - Rx-weak antibiotic, scrubs, compress

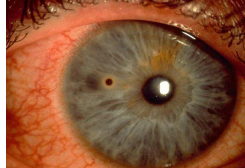
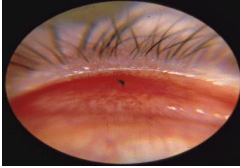

The Red Eye

- Acute Conjunctivitis
viral, bacterial, allergic, neonatal
- Blepharitis
- **Foreign Body**
- Subconjunctival Hemorrhage
- Corneal Ulcer
- Acute Iritis
- Scleritis
- Acute Glaucoma

The Red Eye

- Foreign Body
 - Corneal or conjunctival
 - Toxic Fe ions
 - Physical removal

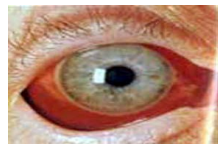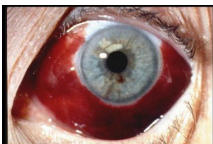
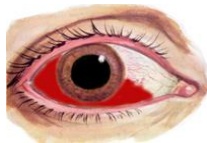


The Red Eye

- Acute Conjunctivitis
 - viral, bacterial, allergic, neonatal
- Blepharitis
- Foreign Body
- Subconjunctival Hemorrhage
- Corneal Ulcer
- Acute Iritis
- Scleritis
- Acute Glaucoma

The Red Eye

- Subconjunctival Hemorrhage
 - “AM” surprise
 - ASA, Plavix, Coumadin use
 - R/O trauma
 - HTN if recurrent

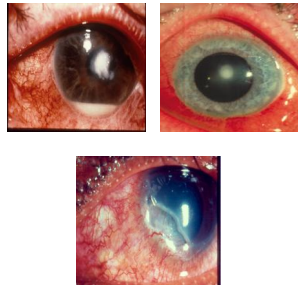


The Red Eye

- Acute Conjunctivitis
viral, bacterial, allergic, neonatal
- Blepharitis
- Foreign Body
- Subconjunctival Hemorrhage
- **Corneal Ulcer**
- Acute Iritis
- Scleritis
- Acute Glaucoma

The Red Eye

- Corneal Ulcer
 - Bacterial, trauma, HSV, Contact lenses
 - Decreased Va, pain, photophobia
 - Broken epithelial surface
 - Potential to melt
 - emergency

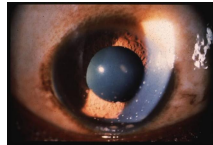
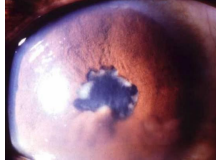


The Red Eye

- Acute Conjunctivitis
viral, bacterial, allergic, neonatal
- Blepharitis
- Foreign Body
- Subconjunctival Hemorrhage
- Corneal Ulcer
- **Acute Iritis**
- Scleritis
- Acute Glaucoma

The Red Eye

- Acute Iritis (Uveitis)
 - Pain, photophobia, tearing
 - Decreased vision
 - Small, poorly reactive pupils
 - Think collagen vascular disease
 - Systemic workup

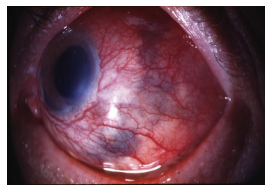


The Red Eye

- Acute Conjunctivitis
 - viral, bacterial, allergic, neonatal
- Blepharitis
- Foreign Body
- Subconjunctival Hemorrhage
- Corneal Ulcer
- Acute Iritis
- **Scleritis**
- Acute Glaucoma

The Red Eye

- Scleritis
 - Localized area of inflammation, tenderness
 - Strong association with systemic disease
 - Think rheumatoid arthritis

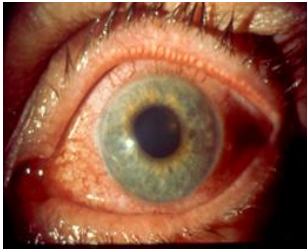

The Red Eye

- Acute Conjunctivitis
 - viral, bacterial, allergic, neonatal
- Blepharitis
- Foreign Body
- Subconjunctival Hemorrhage
- Corneal Ulcer
- Acute Iritis
- Scleritis
- Acute Glaucoma

The Red Eye

- Acute Glaucoma
 - 60-70 years, pain, vomiting, haloes
 - Mid-dilated pupil
 - Hazy cornea
 - Emergency
 - Risk for fellow eye
 - Avoid anticholinergic medications



The Red Eye

- Acute Conjunctivitis
 - viral, bacterial, allergic, neonatal
- Blepharitis
- Foreign Body
- Subconjunctival Hemorrhage
- Corneal Ulcer
- Acute Iritis
- Scleritis
- Acute Glaucoma

The Red Eye

- Differentiate benign from visually threatening causes
- Benign: normal vision, normal pupils
- Visually threatening: decreased vision, abnormal pupils
