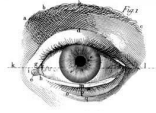


Medical Implications of Sudden Monocular Blindness



Patrick Sibony, MD
Department of Ophthalmology
May, 2007



Sudden Monocular Blindness

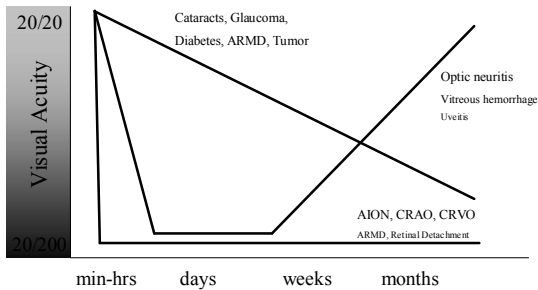
- Discuss the 8 causes of sudden blindness
- Salient symptoms and signs
- Focus on those entities with systemic implications especially for the internist/primary care physician
- Role of the Internist and Primary care physician in the evaluation and management of these disorders.

SuddenBlindness.ppt

2

History

Temporal course



SuddenBlindness.ppt

3

Essential Bedside Eye Exam (for the non Ophthalmologist)


- PERRLA and EOMH
- Visual Acuity
 - (best corrected or pinhole)
- Afferent Pupillary Defect
 - AKA: APD, Marcus Gunn pupil, swinging flashlight sign



SuddenBlindness.ppt

4

Swinging Flashlight Sign



SuddenBlindness.ppt

5

Extended Bedside Eye Examination

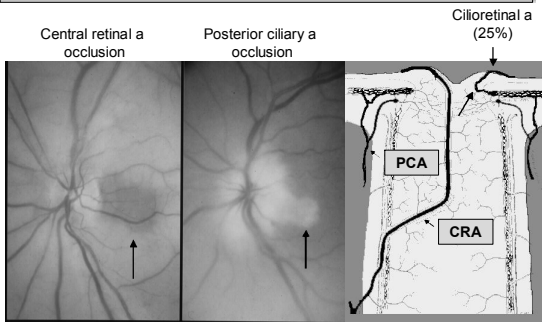
- *Inspect the eye / adnexae*
- *Fundus exam*
 - Dilate with 2.5% neosynephrine
 - disc and macula
- *Eye movements*
- *Confrontation visual fields*



SuddenBlindness.ppt

6

Circulation of the Disc and Retina



Sudden@blindness.ppt

7

Specialty Involvement in various causes of sudden monocular blindness

Internist/Primary Ophthalmologist Neurologist

Retinal artery occlusion
Ischemic optic neuropathy
Retinal vein occlusion

Optic neuritis

Vitreous Hemorrhage

Retinal detachment

Macular degeneration

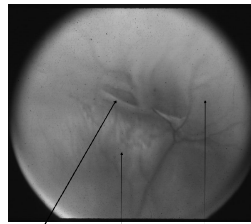
(Psychogenic)

Sudden@blindness.ppt

8

Rhegmatogenous retinal detachment

- Ophthalmologist
- separation between sensory retina and RPE due to vitreous traction
- Peripheral retinal tears
- Trauma and myopia
- **Associated light flashes floaters.**
- sudden visual field loss
- Variable vision, \pm APD



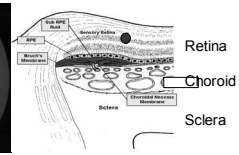
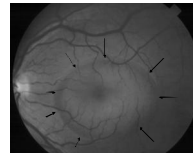
Tear Normal retina Detached retina

Sudden@blindness.ppt

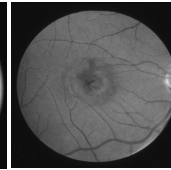
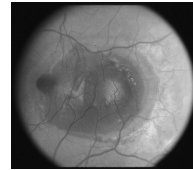
9

Serous/Hemorrhagic PEDs

CSR



ARMD



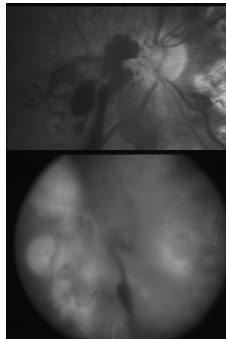
ARMD

Sudden@blindness.ppt

10

Vitreous Hemorrhage

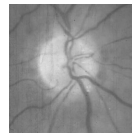
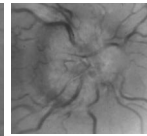
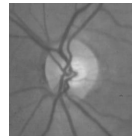
- Sudden, painless onset
- No APD
- Partial view or no view of the fundus.
- Due to
 - Neovascularization DM
 - Retinal Detachment
 - Trauma
 - SAH



Sudden@blindness.ppt

11

Optic Neuritis



- Rapid vision loss over a period of hours to days
- 20-40 years
- **Pain typically with eye movement**
- Variable acuity,
- APD,
- VF loss
- Neurology: MRI, LP and steroids.
- Associated with MS

Sudden@blindness.ppt

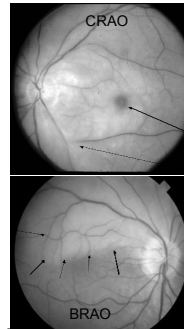
12

Retinal Artery Occlusions

Sudde@lindeus.ppt

13

Retinal Artery Occlusion



- Sudden, painless onset
- \pm premonitory Amaurosis
- APD
- Fundus:
 - Milky white retinal edema
 - Cherry red spot
 - Gaps in blood columns
 - Normal disc
 - Complete (CRAO)
 - Sectoral (BRAO)
 - \pm emboli, vasculitis

14

Features on causes

- Frequently difficult to ascertain the precise mechanism based on the eye exam
- Most cases involve:
 - Local thrombosis due to atherosclerosis
- Less commonly
 - Embolization
 - Vasculitis
 - Vasospasm
 - Hypoperfusion/hypotension

Sudde@lindeus.ppt

15

Associated conditions

- 90% systemic disease
- 65% hypertension
- 25% diabetes
- 25% cardiac valvular disease
 - More likely in patients <45
- 45% carotid atherosclerosis
 - 20% high grade stenosis

Sudde@lindeus.ppt

16

Retinal Artery Occlusion

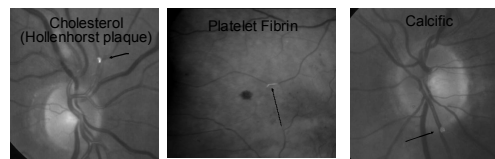
Etiology

- **ATHEROSCLEROSIS, CAROTID DISEASE**
 - (STENOSIS, OCCLUSION, DISSECTION)
- **CARDIAC**
 - (DYSRHYTHMIA, VALVULAR, SBE, PROSTHETIC VALVES, MI, MYXOMA CARDIOMYOPATHY)
- **EMBOLUS**
 - (CALCIFIC, CHOLESTEROL, PLATELET FIBRIN, FAT, TUMOR, SEPTIC, AIR, FB)
- **VASCULITIS**
 - (GCA, LUPUS, IDIOPATHIC, CHURG-STRAUSS, PAN, TAKAYASUS, BEHCETS,)
- **HYPERCOAGULABILITY/BLOOD DYSCRASIA**
 - (INFLAMMATORY BOWEL DISEASE, ESSENTIAL THROMBOCYTHEMIA, LEUKEMIA, PROTEIN C DEFICIENCY, P VERA, ORAL CONTRACEPTIVES, HOMOCYSTINURIA, ANTI-PHOSPHOLIPID AB, HEMOGLOBINOPATHY,
- **MISCELLANEOUS**
 - CAROTID CAVERNOUS FISTULA, MIGRAINE, DRUSEN, OCULAR HYPERTENSION, PREPAPILLARY ARTERIAL LOOPS,
- **TRAUMA**
 - RETROBULBAR ANESTHESIA, INTRANASAL INJECTION, OCULAR PRESSURE, RETROBULBAR HEMMORHAGE, ORBITAL AND RETINAL SURGERY

Sudde@lindeus.ppt

17

Retinal Emboli



-most common

Atheromatous material from the aortic - carotid system
-Needs to be evaluated even if the patient is asymptomatic

Carotid or cardiogenic thrombosis

-Least common

-calcified cardiac valves or atheromatous carotid plaques

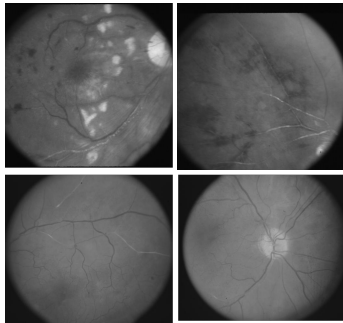
•Retinal arterial emboli

- associated with increased mortality primarily from cardiac disease.
- 56% / 9 years compared to 27% in an aged matched controls

Sudde@lindeus.ppt

18

Multiple Branch Occlusions



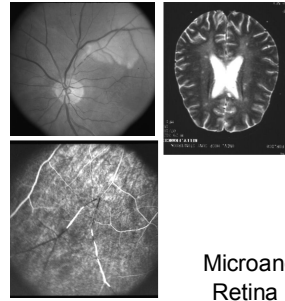
Lupus

Antiphospholipid Ab Syndrome

Sudder@lindeus.ppt

19

BRAO with CNS findings



- 40 yo wm
- Multiple BRAO
- Mental status and other focal hemispheric signs
- Tinnitus

Microangiopathy of Brain and Retina (Susac's Syndrome)

Sudder@lindeus.ppt

20

Management of Retinal a Occlusion

- Short term immediate treatment
- Urgent systemic workup
- Systemic treatment

Sudder@lindeus.ppt

21

CRAO: short term ocular treatment

- Emergent referral to an ophthalmologist
- Experimental occlusions: 90 minutes
- If the patient is seen within 8(?) hours of onset
- *Anterior chamber paracentesis*
- ? IV Diamox or Mannitol to lower IOP
- ? 95% O₂ / 5% CO₂
- ? ocular massage to dislodge embolus
- ? Anti fibrinolytic agents

Sudder@lindeus.ppt

22

CRAO: urgent systemic workup

- R/O diabetes, hypertension, hyperlipidemia, CAD
- **Carotid evaluation:**
 - Carotid duplex scan and/or MRA
 - cerebral angiography for high grade stenosis.
- **Cardiac evaluation**
 - cardiac echo ,
- **Vasculitis :**
 - ESR, ANA, Antiphospholipid antibody, temporal artery biopsy etc.
- **Hematologic** assesment especially in young patients

Sudder@lindeus.ppt

23

CRAO: systemic treatment

- Depends on the cause
- Consider the use of
 - Endarterectomy
 - Anticoagulation (Aspirin vs Heparin/Coumidan)
 - Valve surgery
 - Steroids, Immunosuppression

Sudder@lindeus.ppt

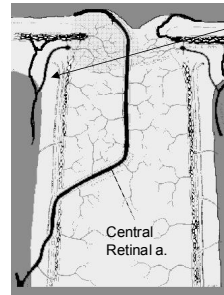
24

Anterior Ischemic Optic Neuropathy

Sudder@indiana.ppt

25

Anterior Ischemic Optic Neuropathy

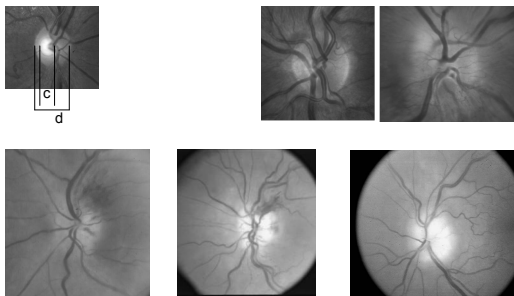


- Occlusion of the posterior ciliary artery with optic disc infarction
- Optic disc is invariably swollen in the acute stage
- Retrobulbar Ischemic optic neuropathy is rare. Diagnosis of exclusion after compression or infiltration are ruled out.

Sudder@indiana.ppt

26

Fundus in AION



Sudder@indiana.ppt

27

Anterior Ischemic Optic Neuropathy

Etiology

- **Nonarteritic AION**
 - Hypertension
 - diabetes.
 - Anemia, blood loss,
 - Systemic hypotension
 - Malignant Hypertension
 - Renal failure
 - Radiation
 - Coagulopathy
 - **Arteritic AION**
 - Giant cell arteritis (GCA)
 - other vasculitides
- Not: carotid or embolic !**
- Other :
 - Drugs: ?Interferon alpha, ?sildenafil, ?amioderone
 - Ocular: optic disc drusen, post op (cataract, glaucoma, LASIK)
 - Misc: sleep apnea, glaucoma, migraine

Sudder@indiana.ppt

28

Non arteritic-AION

- 50-65 F or M
- PMH: hypertension (diabetes)
- painless, apoplectiform onset of monocular vision loss
- 20/20 to no light perception (NLP), Dyschromatopsia, APD
- Optic disc is invariably swollen in the acute stage
- Prognosis: slight improvement with persistent defects in vision
- second eye in 25 - 40% over 5 years
- There is no effective treatment
- Prednisone, ASA, Antiplatelets, Heparin and surgical fenestration have failed to show any benefits. ? ASA may reduce risk of second eye involvement.

Sudder@indiana.ppt

29

Arteritic AION

- Most common cause of blindness in GCA
 - 95% AION 5% CRAO
- Adequate treatment must be started immediately to avoid second eye involvement.
- Occult GCA : normal ESR in 10 – 15% of patients with AION; sometimes without symptoms of PMR.

Sudder@indiana.ppt

30

GCA: AN 167152

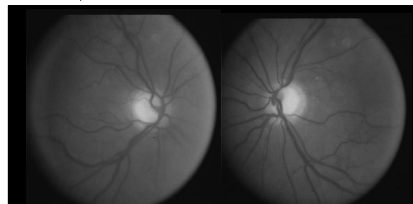
WK	Clinical History	Vision	Steroids
0	72 WF, Headaches, ESR = 105, <u>positive biopsy for GCA</u> , Headaches resolved with treatment.	Normal	80mg
5w	Steroids gradually tapered New onset scotoma OD (ophthalmologist)	CF OD (AION)	30 mg
5w +3d	Calls to report deterioration of vision OD . Told by ophthal to come in on Monday. Continue prednisone	NLP OD 20/20 OS	30 mg
6 w	Phone call. Vision in the unaffected eye OS is transiently blacking out. "my vision is worse" Told by the ophthal to come in tomorrow	NLP OD HM OS	30 mg
	Admitted for IV solumedrol		1gIV

Sudder@lincoln.ppt

31

AN 167152

+3 m	OD	OS
Vision	NLP	NLP
Tension	10	12
Pupils	Sluggish	Sluggish



Sudder@lincoln.ppt

32

Comments on Case AN

- Second eye involvement in GCA
 - Within 1 week in >70% cases, untreated (or inadequately treated)
- What is adequate steroid coverage in AION/GCA at the start and during taper
- How urgently do you treat patients with GCA who complain of visual loss
- The need for communication between ophthalmologist and internist in the management of these cases
- Catastrophic implications for the patient and serious legal issues for the health care providers.

Sudder@lincoln.ppt

33

Hayreh. Visual deterioration in GCA while on high dose steroids. *Ophthalmology* 2003. 110:1204

- Vision can deteriorate in 5-15% of patients on steroids
- Deterioration while on adequate doses of steroids usually develops within the first 5 days.
- Thrombocytosis may be a risk factor for progression
- Many examples in the literature of second eye progression despite the use of prednisone and IV solumedrol

Sudder@lincoln.ppt

34

Corticosteroids in the Treatment of GCA

- No studies have established the ideal dose of steroids
- No clear evidence that iv is more effective than po corticosteroids (Hayreh et al. 2003)
- IV is indicated in patients with impending vision loss (premonitory amaurosis fugax, unilateral vision loss with or without early signs in the contralateral eye)
- Anecdotal reports of reversal of vision loss on IV solumedrol
- Oral prednisone 80-100mg with vision loss (at least).
- Solumedrol 1 gm IV PB QD for 3-5 days (? 2 gms and 4 gms have been given) followed by po pred. or...
- Dexamethasone 150mg q8 x 3-5 days followed by po pred

Sudder@lincoln.ppt

35

Corticosteroids in the Treatment of GCA

How long to treat

- There are no hard rules.
- Based primarily on ESR and CRP. Symptoms are used but not always reliable indicator of visual complications.
- Maintain high dose of po prednisone until the ESR and CRP reach its lowest stable value (usually 2 weeks); then start gradual taper (10mg/month).
- Frequent followup intervals in the first 3 months or down to low stable maintenance dose.
- Maintenance dose (5 mg – 7.5mg) for 1-2+ years.
- If steroids fail, consider Azothioprine, MTX, Cytoxan or cyclosporin

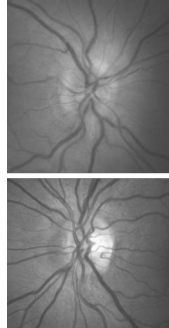
Sudder@lincoln.ppt

36

Middle aged woman with sudden blindness

- 44 yo wf; no medical problems
- h/o uncomplicated liposuction of thigh, belly and flank under general anesthesia
- "usual post op ecchymosis"
- 48 h later noted sudden, painless field loss od
- 20/20 ou, apd od, inferior altitudinal field loss od

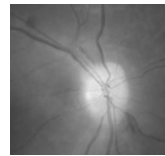
• Hct 18, HgB 6



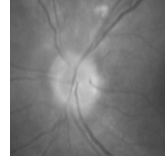
Sudden@Blindness.ppt

37

Elderly man with sudden blindness



- 64 year old wm, sudden painless, vision loss OD
- 20 pound weight loss/ 6 months on a diet; fatigue, no headaches
- Exam
 - 20/40 OD, 20/25 OS, APD OD
 - Altitudinal visual field loss OU
- Blood pressure 150/80 mm Hg.

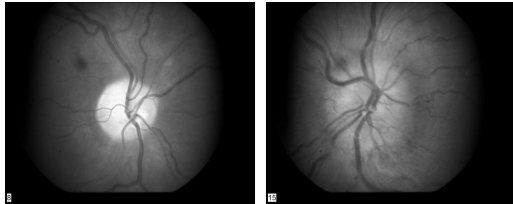


- Hct 15; Hb 4.5
- Chronic Renal Failure.

Sudden@Blindness.ppt

38

PseudoFoster Kennedy Syndrome in 16 yo Male

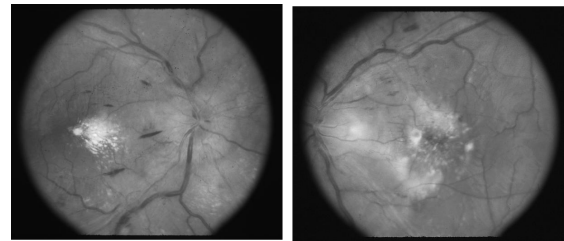


Anti Phospholipid Antibody Syndrome

Sudden@Blindness.ppt

39

Sudden sequential vision loss and headaches in 19 yo Male



Acute Hypertensive Neuroretinopathy
BP 220/160, Pheochromocytoma

Sudden@Blindness.ppt

40

Medications implicated in AION

- Medications for Erectile dysfunction
 - Viagra, Cialis, Levitra
- Amiodarone
- Interferon beta

Sudden@Blindness.ppt

41

Erectile Dysfunction Drugs

- 43 reported cases: 38 viagra; 4 Cialis; 1 Levitra
 - 1 case with rechallenge history
- 170 million prescriptions taken by 23 million men
- 100 clinical studies; n= 13,000 patients, no AION; Most patients had other risk factors for AION

• **Conclusion:** "Probable" (not "certain")

- Contributory factor in a multifactorial disorder

- **FDA recommendations:**
 - Stop taking med with sudden vision loss
 - Discuss potential increased risk with patients prior AION (? All)
- *Avoid in patients with prior unilateral AION or significant retinovascular disease*

Sudden@Blindness.ppt

42

Amiodarone-associated Optic Neuropathy

- α β antagonist for cardiac arrhythmias
- ? \approx 1.79% of patients on the medication
- Insidious bilateral disc edema, normal vision, big blind spots
- “possible” link (not “probable” nor “certain”)
- Benefits far outweigh the risk
- Cardiologist should decide based on risks of discontinuation, alternatives

Suttorf@blindness.ppt

43

Interferon α – associated Optic Neuropathy

- Antiviral, antitumoral, antiangiogenic, immunomodulatory
- Hepatitis C, Leukemias, Myeloma, Thrombocytosis
- Reversible, asymptomatic, dose-related vascular retinopathy
- Anecdotal evidence for AION
 - 12 cases, 7 bilateral
 - 1w – 7 months after starting the drug
- Possible association.

Suttorf@blindness.ppt

44

Important points for the internist

- Do not lower pressure too aggressively
- Cautious steroid taper
- Insist on disc edema, otherwise consider other causes like tumor.
- Workup those cases with atypical features:
 - Young
 - Bilateral
 - Constitutional symptoms/systemic disease

Suttorf@blindness.ppt

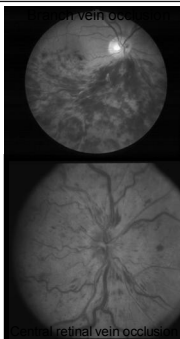
45

Retinal Vein Occlusions

Suttorf@blindness.ppt

46

Retinal Vein Occlusion



- Elderly
- Painless, sudden loss
- Variable acuity, \pm APD
- Distinctive, if not pathognomonic fundus findings.
- Unilateral

47

Vein Occlusion

Associations

- **Glaucoma** (25-70%)
- **HBP**(35-50%),
- **Diabetes**(10-15%) ,
- **Hyperlipidemia** (10%)

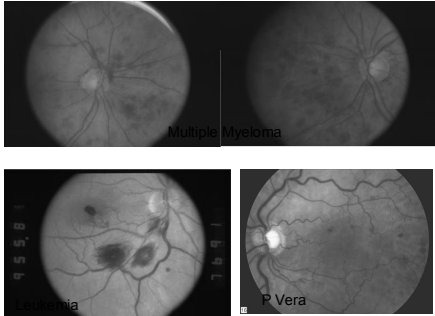
Most patients have no other systemic disorders; however young patients, bilaterality, thrombotic history or the presence of phlebitis should lead to a more extensive evaluation.

- **Blood dyscrasias:**
 - multiple myeloma, Waldenstroms, Leukemia, P Vera, Thrombocythemia, cryoglobulinemia, sickle cell
- **Coagulopathy:**
 - Antiphospholipid antibody, Protein C and S deficiency, APC resistance, estrogens, pregnancy
- **Retinal vasculitis (periphlebitis):**
 - sarcoidosis, Eales disease, Behcet's, uveitis,
- **Other**
 - Carotid cavernous fistula, retrobulbar anesthesia,

Suttorf@blindness.ppt

48

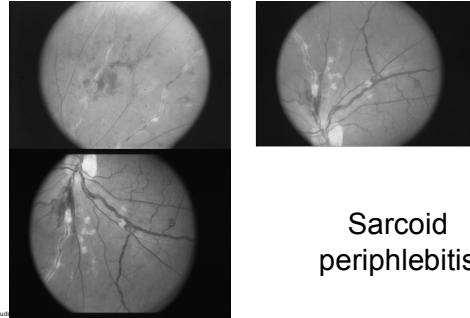
CRVO with Blood Dyscrasias



Sudde@lindnae.ppt

49

26 yo WM



Sarcoid
periphlebitis

Sud

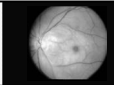
50

Summary:

sudden monocular blindness

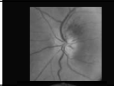
Retinal artery occlusions:

Branch, Central



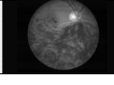
Ischemic optic neuropathy

Nonarteritic, Arteritic



Retinal vein occlusions

Branch, Central



Etiology/workup

- Carotid / cardiac
- HBP, DM,
- Vasculitis
- Hypercoagulability
- Blood dyscrasias

- Optic neuritis (pain)
- Ocular: vitreous hemorrhage, ARMD, Retinal detachment, psychogenic.

Sudde@lindnae.ppt

51