

VISUAL FIELDS

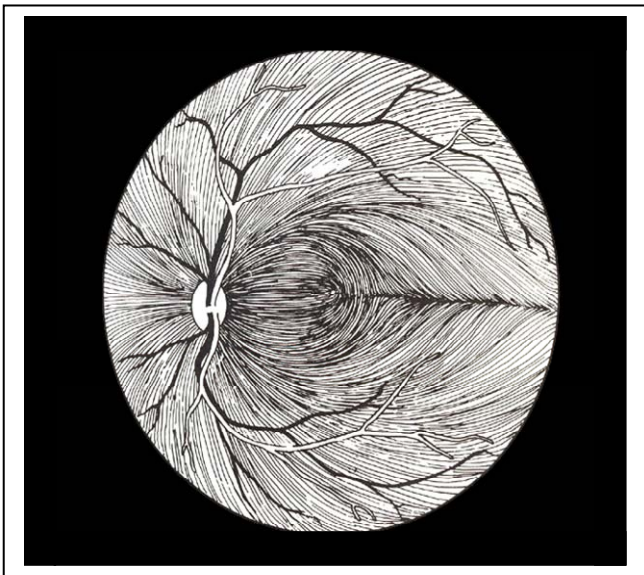
Review the basic anatomy of the visual afferent pathways before starting this summary. Have a diagram of the visual pathways handy as you work through each of these statements.

- Be clear about the distinction between the visual field (as the patient sees it) and the anatomical visual pathways. Remember the patients image projected onto the visual pathways is upside down and inverted i.e.....

temporal visual field projects to the nasal hemiretina
upper visual field projects to the inferior hemiretina

PRECHIASMAL VISUAL FIELDS

- Familiarize yourself with the distribution of nerve fibers in the retina. Fibers of the macular ganglion cells take a direct route to the nerve in the papillomacular bundle. The extramacular axons converge on the optic nerve in an arcuate fashion surrounding the papillomacular bundle. Upper fibers remain in the upper half of the retina and lower fibers remain in the lower half .
- Lesions of the optic nerve tend to cause field cuts that reflect this anatomy i.e. "nerve fiber bundle layer defects" (NFBL defects) .



- There are three types of NFBL defects
 - central scotomas** lesions involving the papillomacular bundle; a *cecocentral scotoma* is a central scotoma that incorporates the blind spot. Both are typical of optic neuritis and macular disease.
 - arcuate defects** (*Bjerrum's scotomas*) are typically seen in glaucoma
 - step defect** (*nasal or temporal step*) is a peripheral notch that respects the horizontal meridian. In its complete form , an *altitudinal defect* involves the entire lower or upper half of the visual field. Typically seen in AION.

CHIASMAL VISUAL FIELDS

- Visual field loss that respects the vertical meridian (that vertical line that bisects the visual field through the fixation point) localizes to either the chiasm, optic tract or visual radiations .
- Monocular respect for the horizontal meridian is more typical of prechiasmal (optic nerve or retinal) lesions
- Nasal hemiretinal fibers (temporal visual field) cross at the chiasm and enter the contralateral visual radiations; temporal hemiretinal fibers (nasal visual field) remain uncrossed throughout the visual pathways. Because the crossed fibers of the chiasm appear to be most susceptible to injury the hallmark of chiasmal involvement is a **bitemporal hemianopsia**.
- **Junctional scotoma:** is a common manifestation of chiasmal involvement characterized by a central scotoma in one eye and a temporal field cut of any kind in the other eye. Assymmetric compression of the prechiasmal portion of the optic nerve accounts for the central scotoma. Because some of the crossing nasal retinal fibers loop slightly into the contralateral

optic nerve as it passes through the chiasm, this same site of compression will cause a small contralateral supertemporal defect.

RETROCHIASMAL VISUAL FIELDS

- Retrochiasmal visual field defects are *homonymous* in that they respect the vertical meridian and involve the same side of the visual field from both eyes. For ex. a left homonymous hemianopsia affects temporal hemifield of left eye and the nasal hemifield of the right eye. Remember that the retrchiasmal pathways are comprised of both crossed and uncrossed fibers.
- hemianopic defects that are identical in shape on both sides are said to be congruent. If the defects differ significantly between eyes we describe this difference as being incongruent. If a hemianopsia is complete, that is involving the entire hemianopic field the degree of congruency cannot be determined.
- A *homonymous hemianopsia is contralateral to the affected retrochiasmal visual radiations*. Thus a left homonymous hemianopsia

is due to a retrochiasmal on the right. This includes the optic tract, geniculate, parietal, temporal or occipital lobes.

- *Upper fibers of the visual pathway maintain an upper location throughtout the visual afferent system*. The same holds true for lower visual fibers. That is the fibers from the upper retina project to the upper optic nerve and the upper visual radiations. Thus a superior homonymous quadrantanopsia ("pie in the sky") localizes to the inferior portion of the visual radiations in the temporal lobe or the inferior portion of the occipital lobe. An inferior homonymous quadrantanopsia localizes to the parietal lobe or the upper portion of the occipital lobe.
- *Occiptial hemianopsias are typically very congruent* and may spare the macula portion (cental 5-10 degrees) of the visual field.
- In contrast retrochiasmal hemianopsias consequent to lesions of the *optic tract, temporal lobe or pareital lobe tend to be incongruent*.

LOCALIZATION OF THE AFFERENT VISUAL PATHWAYS

| | PRECHIASMAL | CHIASMAL | RETROCHIASMAL |
|----------------------|--|--|--|
| VISUAL ACUITY | DECREASED | DECREASED | NORMAL |
| COLOR VISION | ABNORMAL | ABNORMAL | NORMAL |
| PUPILS | APD | APD | NORMAL |
| FUNDUS | ODE, OA, (NL EARLY) | OA (NL,EARLY) | NORMAL |
| VISUAL FIELDS | CENTRAL SCOTOMA ALTITUDNAL ARCUATE | BITEMPORAL JUNCTIONAL SCOTOMA OPTIC TRACT: HOMONYMOUS | HOMONYMOUS |
| ETIOLOGY | OPTIC NEURITIS AION | PITUITARY ADENOMA CRANIOPHARYNGIOMA MENINGIOMA | CVA TUMORS AVMS |
| | OPTIC NEURITIS YOUNG, RAPID VISION LOSS, PAIN AION ELDERLY, HBP, DM, RAPID PAINLESS VISION LOSS | ENDOCRINE DYSFUNCTION (AMENORRHEA, IMPOTENCE) HEADACHES, SLOW VISION LOSS | RAPID OR SLOW VISION LOSS; HEMISPHERIC SIGNS |

APD: AFFERENT PUPILLARY DEFECT; ODE: OPTIC DISC EDEMA; OA: OPTIC ATROPHY; NL: NORMAL

