

## Ocular Examination

Stuart Fourman, M.D.  
Department of Ophthalmology  
State University of New York at Stony  
Brook

---

---

---

---

---

---

---

---

## Ocular Examination

- Eye Exam History
  - Medical History
    - ASCVD, DM, thyroid
  - Symptoms besides vision loss
    - Pain
    - Photopsia
    - Floaters
  - Other eye surgery

---

---

---

---

---

---

---

---

## Ocular Examination

- Eye Exam
  - Vision
  - Pupils
  - Motility
  - External exam
  - Ophthalmoscopy
  - Visual Fields



---

---

---

---

---

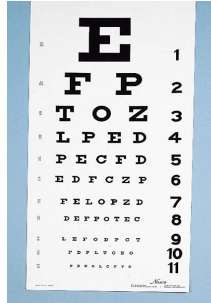
---

---

---

## Ocular Examination

- Vision
  - Hand card vision with reading glasses
  - Counting Fingers (CF)
  - Hand Motions (HM)
  - Light Perception (LP)
  - No light perception (NLP)
  - Central, steady, maintained (CSM)



---

---

---

---

---

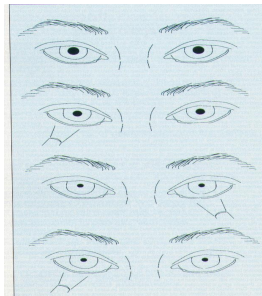
---

---

---

## Ocular Examination

- Pupils
  - most important exam finding
  - cannot be faked
  - no patient input
  - NO PERRLA
  - NO WNL



---

---

---

---

---

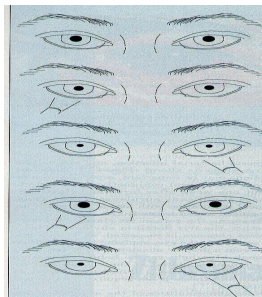
---

---

---

## Ocular Examination

- Afferent Pupil Defect
  - swinging flashlight
  - optic nerve or retinal damage



---

---

---

---

---


---

---

---

## Ocular Examination

- Afferent Pupil Defect (APD)
- Most important point of this talk



---

---

---

---

---

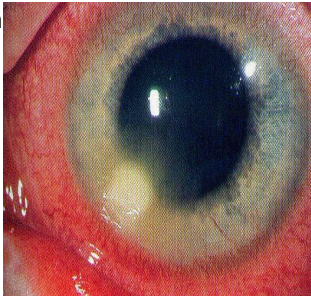---

---

---

## Ocular Examination

- External Eye Exam
  - lids
  - conjunctiva
  - cornea
  - anterior chamber
  - lens
  - iris



---

---

---

---

---

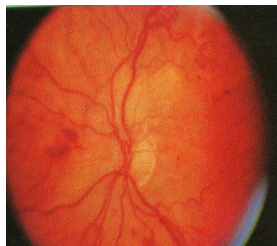
---

---

---

## Ocular Examination

- Ophthalmoscopy
  - vitreous
  - optic nerve
  - retina
  - dilate using neosynephrine 2.5%, one drop every 5 min twice



---

---

---

---

---

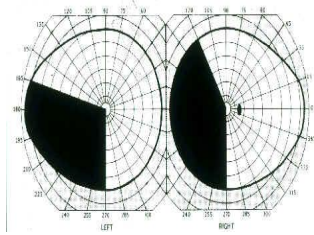
---

---

---

## Ocular Examination

- Visual Fields
  - confrontation
  - Goldmann
  - Automated



---

---

---

---

---

---

---

---